

Case Summary

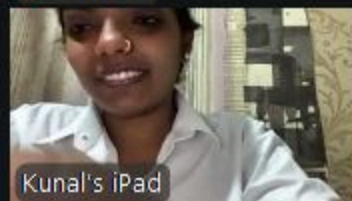
- Mrs ABC, 55 years of age, P3I3, tubectomised presented with complaints of mass per vagina since 2 years and difficulty in voiding since 1 month, On examination general examination findings are normal and viatals are stable. On local examination cervix was seen 5 cms outside th intraoitus, vaginal mucosa was atropic, cystocele was present and and mass was reducible. On examination was posterior wall both enterocele and rectocele were present. Intraoitus is gaping and tone of laevator ani was poor

Dr Srinivas K Jois

Dr Srinivas K Jois

Suchitra


Suchitra



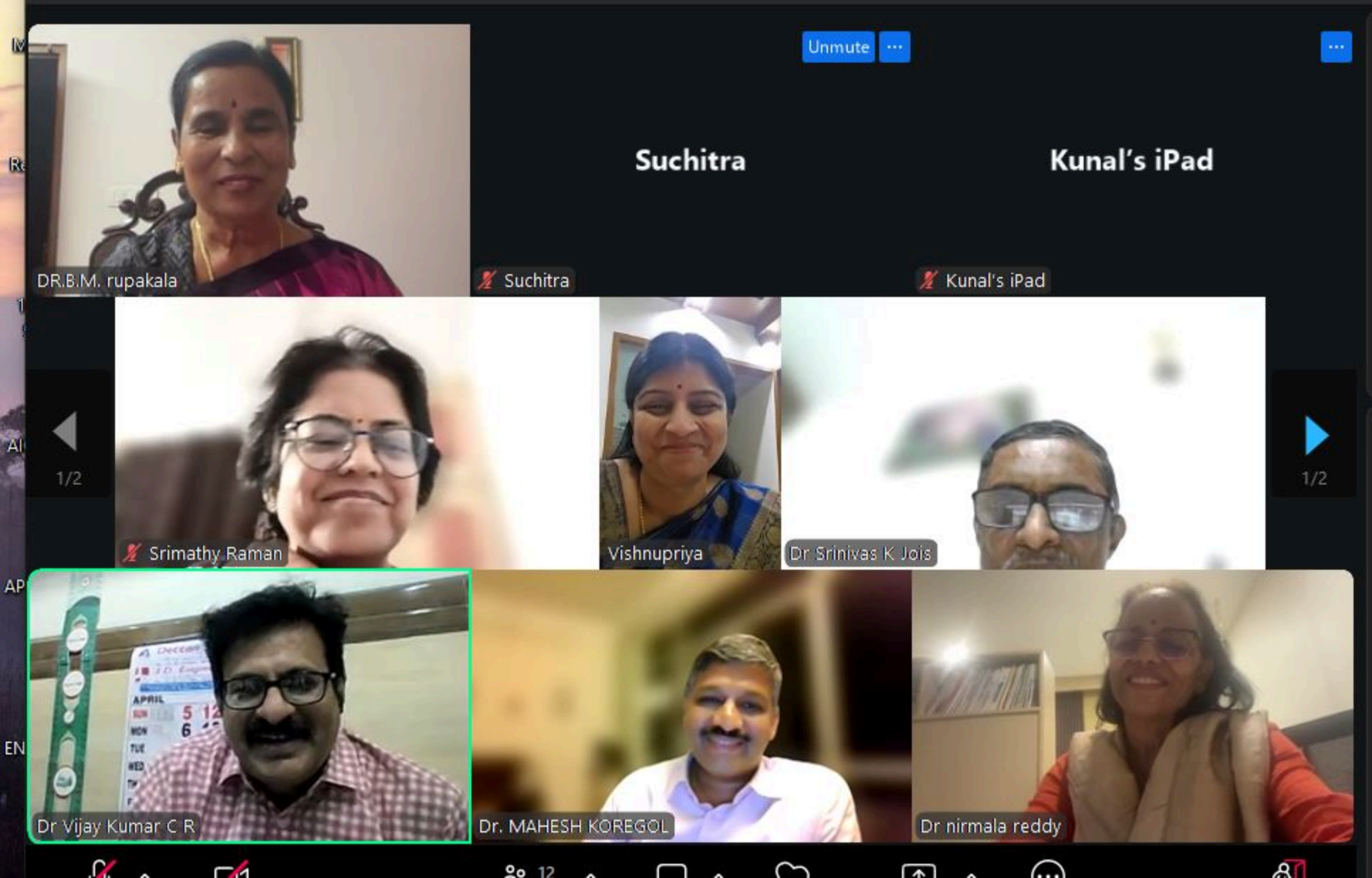
Kunal's iPad

D

DR.B.M. rupakala



Dr.Nagamani Tyagaraj



Unmute ...

...

Suchitra

Kunal's iPad

DR.B.M. rupakala

Suchitra

Kunal's iPad

1/2

Srimathy Raman

Vishnupriya

Dr Srinivas K Jois

1/2

Dr Vijay Kumar C R

Dr. MAHESH KOREGOL

Dr nirmala reddy

12

REC LIVE

Switch camera
Switch to active speaker

Dr Vijay Kumar C R

Dr. MAHESH KOREGOL

DR.B.M. rupakala

Dr.Nagamani Tyagaraj

Kunal's iPad


SANDHIYA

SWASTIKA (CLIRNET)

Vishnupriya

Srimathy Raman

Unmute Stop video Chat Participants 11 Start share More Leave



Srimathy Raman

Vishnupriya

Dr Srinivas K Jois

Vishnupriya

Dr Srinivas K Jois



2/2

SWASTIKA (CLIR...



Dr. MAHESH KOREGOL

Dr Vijay Kumar...



2/2

Dr Vijay Kumar C R

Dr nirmala reddy

Sandhiya



Dr.Nagamani Tyagaraj

Dr nirmala reddy

Sandhiya



Audio



Video



Participants 12



Chat



React



Share



More



Leave

REC LIVE



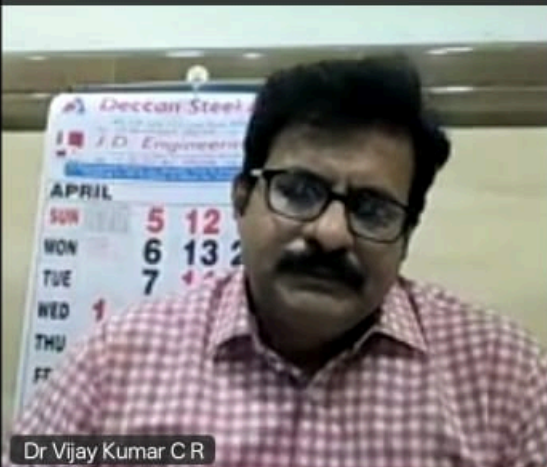Switch camera



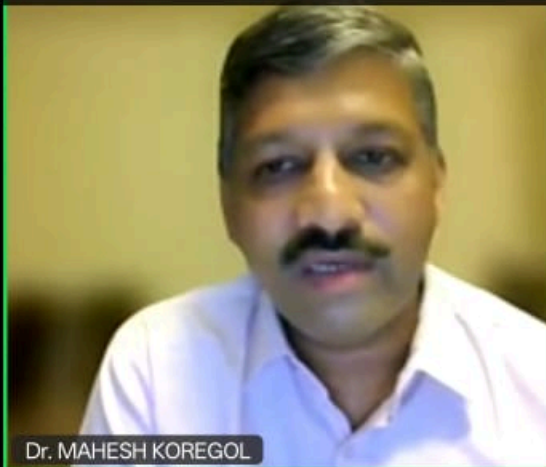Switch to active speaker



Dr Srinivas K Jois



Dr Vijay Kumar CR



Dr. MAHESH KOREGOL



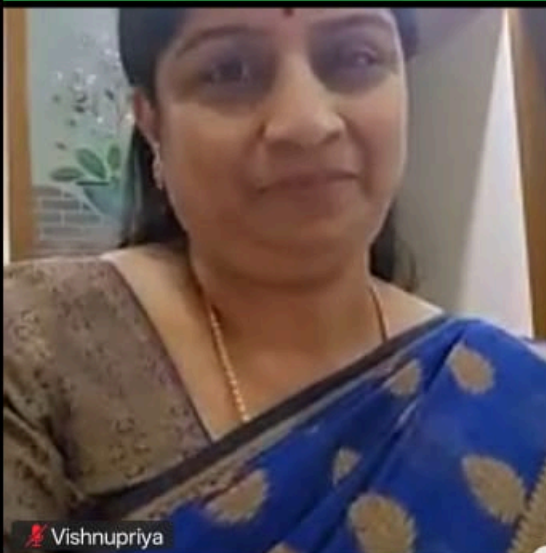
DR.B.M. rupakala



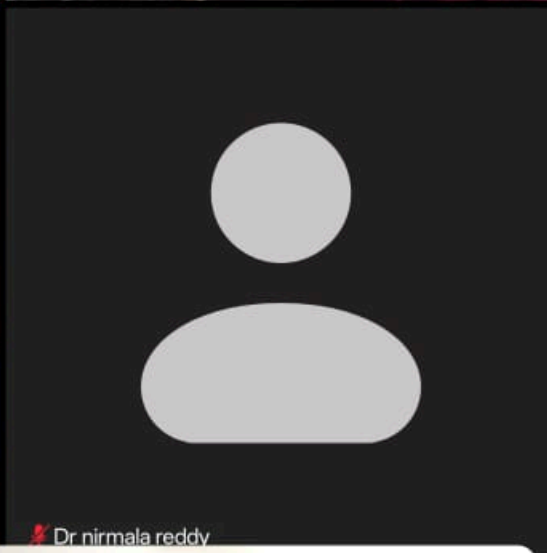
Dr. Nagamani Tyagaraj





SANDHIYA



Vishnupriya



Dr nirmala reddy



Srimathy Raman

Unmute Stop video Chat Participants 11 Start share More Leave



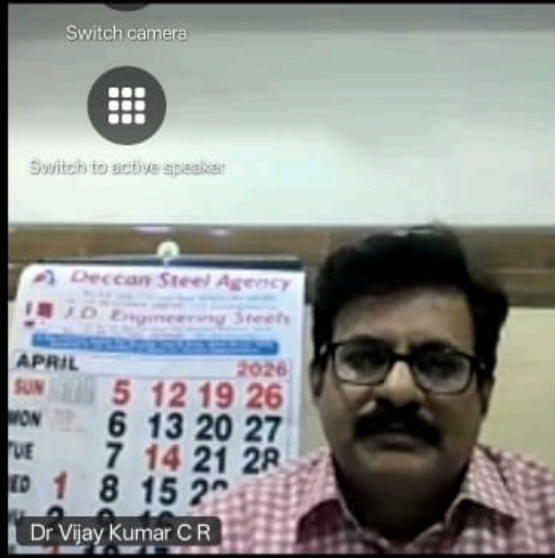
LIVE



Switch camera



Switch to active speaker



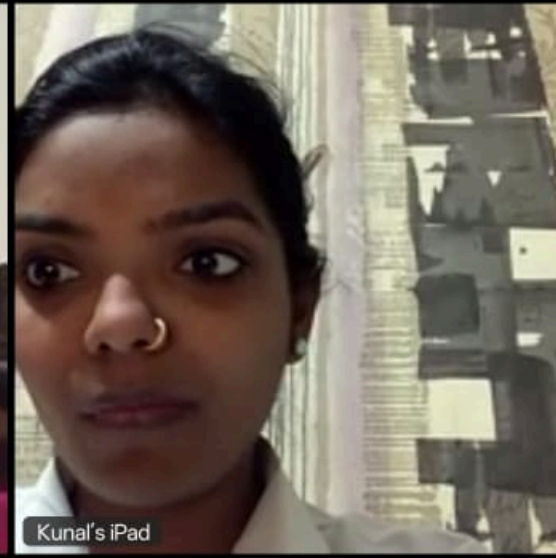
Dr Vijay Kumar CR



Dr. MAHESH KOREGOL



DR.B.M. rupakala




Kunal's iPad



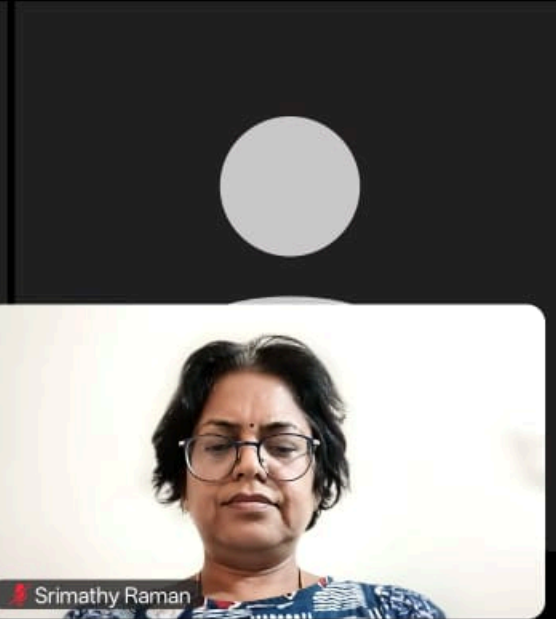
Vishnupriya



Dr Srinivas K Jois



SANDHIYA



Srimathy Raman



Unmute



Stop video



Chat



Participants 9



Start share



More



Leave

Case Summary

- Mrs ABC, 55 years of age, P3I3, tubectomised presented with complaints of mass per vagina since 2 years and difficulty in voiding since 1 month, On examination general examination findings are normal and viatals are stable. On local examination cervix was seen 5 cms outside th intraoitus, vaginal mucosa was atropic, cystocele was present and and mass was reducible. On examination was posterior wall both enterocele and rectocele were present. Intraoitus is gaping and tone of laevator ani was poor



Vishnupriya

Dr Srinivas K Jois

Srimathy Raman

Vishnupriya

Dr Srinivas K Jois

SWASTIKA (CLI...



Dr Vijay Kumar...

SWASTIKA (CLIRNET)

Dr. MAHESH KOREGOL

Dr Vijay Kumar C R

Dr nirmala reddy

Sandhiya



Dr nirmala reddy

Sandhiya

Dr.Nagamani Tyagaraj



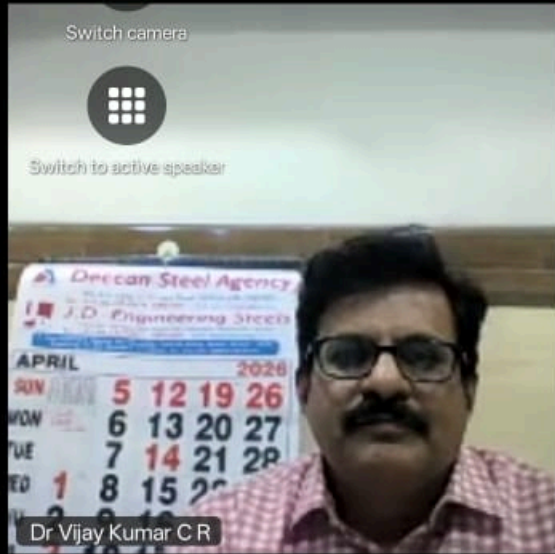
LIVE



Switch camera



Switch to active speaker



Dr Vijay Kumar CR



Dr. MAHESH KOREGOL




DR.B.M. rupakala



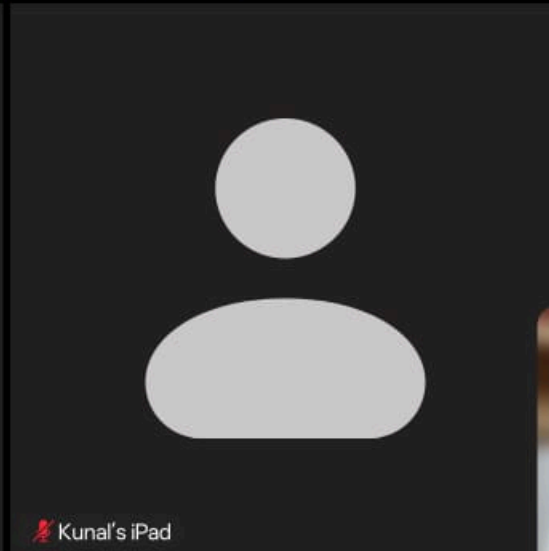
SANDHIYA



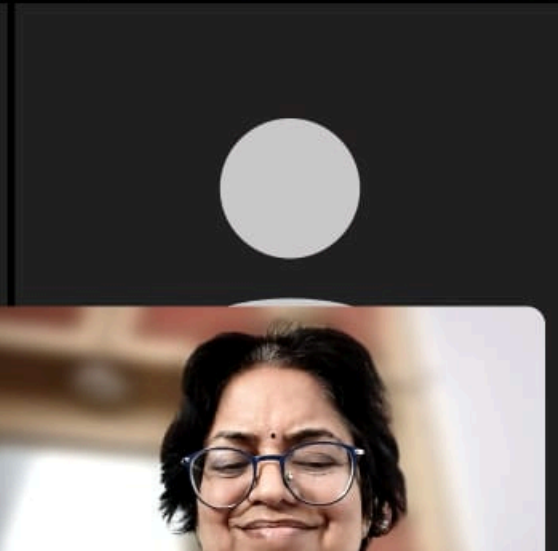
Vishnupriya



Dr Srinivas K Jois



Kunal's iPad



Srimathy Raman



Mute



Stop video



Chat



Participants



Start share



More



Leave

Case Summary

- Mrs ABC, 55 years of age, P3I3, tubectomised presented with complaints of mass per vagina since 2 years and difficulty in voiding since 1 month, On examination general examination findings are normal and viatals are stable. On local examination cervix was seen 5 cms outside th intraoitus, vaginal mucosa was atropic, cystocele was present and and mass was reducible. On examination was posterior wall both enterocele and rectocele were present. Intraoitus is gaping and tone of laevator ani was poor



Suchitra

DR.B.M. rupakala

Suchitra

Kunal's iPad



Vishnupriya

Srimathy Raman

Vishnupriya

Dr Srinivas K Jois

Dr Srinivas K Jois

SWASTIKA (C...



Dr Vijay Kuma...

SWASTIKA (CLIRNE...

Dr. MAHESH KORE...

Dr Vijay Kumar C

Unmute ...

...

