

Aasya (CLIRNET)

Suchitra



Thejavathy Venkatesh



Srimathy Raman

(CLIRNET)


Suchitra



1/2



1/2



Parineeta Bansal



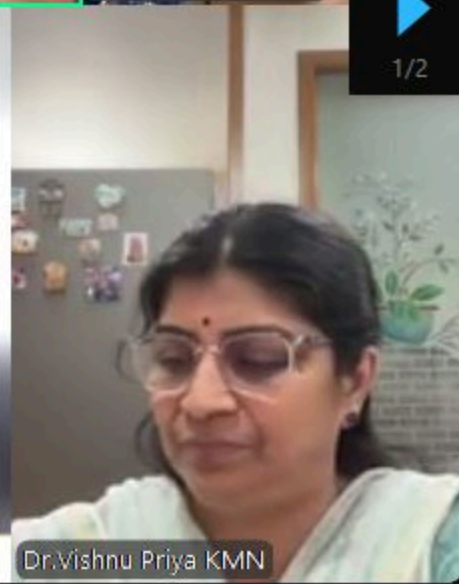
Prof. Prakash Mehta



Dr Mahesh Koregol



Dr Rajini Uday



Dr. Vishnu Priya KMN

WPS Office window showing a presentation slide titled "Hypertensive Disorders in Pregnancy". The slide content includes the title, the presenter's name "Dr. Parineeta Bansal", and her affiliation "3rd Year OBG Resident, Vydehi Medical College". The interface includes a top menu bar with options like File, Home, Insert, Design, Transitions, Animations, Slide Show, Review, View, Tools, Student Tools, and WPS AI. A left sidebar shows a slide outline with 6 slides. The bottom status bar indicates "Slide 1 / 24" and "Default Design".

Hypertensive Disorders in Pregnancy

Dr. Parineeta Bansal
3rd Year OBG Resident
Vydehi Medical College


Outline Slides

- 1 Hypertensive Disorders in Pregnancy
- 2
- 3
- 4 History of Preexisting Hypertension
- 5 History of Preexisting Hypertension
- 6 History of Preexisting Hypertension

Click to add notes

Slide 1 / 24 Default Design

Video conference interface showing four participants in a grid. The top-left participant is a man with a mustache and glasses, identified as "mvpai". The top-right participant is a woman with glasses, identified as "Suchitra". The bottom-left participant is a woman, identified as "Parineeta Bansal". The bottom-right participant is a man, identified as "Prof. Prakash M...". The background of the top-left video shows a building with "SMIMS SIKKIM MANIPAL UNIVERSITY" signage.



mvpai

Suchitra

Suchitra

Dr. Vishnu Priy...

Parineeta Bansal

Prof. Prakash M...

WPS Office Case presentation post men... Upgrade Now

File Home Insert Design Transitions Animations Slide Show Review View Tools Premium WPS AI Not uploaded Share

Outline Slides

FIGO 2023	Description	FIGO 2009
IA	Disease limited to the endometrium OR non-aggressive histological type, i.e. low-grade endometroid, with invasion of less than half of myometrium with no or focal lymphovascular space involvement (LVS) OR good prognosis disease	IA, IIA
IA1	Non-aggressive histological type limited to an endometrial polyp OR confined to the endometrium	IA
IA2	Non-aggressive histological types involving less than half of the myometrium with no or focal LVS	IA
IA3	Low-grade endometroid carcinomas limited to the uterus and ovary	IIA
IB	Non-aggressive histological types with invasion of half or more of the myometrium, and with no or focal LVS	IB
IC	Aggressive histological types limited to a polyp or confined to the endometrium	IA
IIA	Invasion of the cervical stroma of non-aggressive histological types	II
IIB	Substantial LVS of non-aggressive histological types	IA, IB, II
IIC	Aggressive histological types with any myometrial involvement	IA, IB, II
IIIA	Invasion of uterine serosa, adnexa, or both by direct extension or metastasis	IIIA
IIIA1	Spread to ovary or fallopian tube (except when meeting stage IA3 criteria)	IIIA
IIIA2	Involvement of uterine subserosa or spread through the uterine serosa	IIIA
IIIB	Metastasis or direct spread to the vagina and/or the parametria or pelvic peritoneum	IIIB, IVB
IIIB1	Metastasis or direct spread to the vagina and/or the parametria	IIIB
IIIB2	Metastasis to the pelvic peritoneum	IVB
IIIC	Metastasis to the pelvic or para-aortic lymph nodes or both	IIIC
IIIC1	Metastasis to the pelvic lymph nodes	IIIC1
IIIC1i	Micrometastasis	IIIC1
IIIC1ii	Macrometastasis	IIIC1
IIIC2	Metastasis to para-aortic lymph nodes up to the renal vessels, with or without metastasis to the pelvic lymph nodes	IIIC2
IIIC2i	Micrometastasis	IIIC2
IIIC2ii	Macrometastasis	IIIC2
IVA	Invasion of the bladder mucosa and/or the intestinal/bowel mucosa	IVA
IVB	Abdominal peritoneal metastasis beyond the pelvis	IVB
IVC	Distant metastasis, including metastasis to any extra- or intra-abdominal lymph nodes above the renal vessels, lungs, liver, brain, or bone	IIIC, IVB

Click to add notes AI Speech Generator

Slide 29 / 44 Office Theme

Dr.Vishnu Priya...


Dr.Vishnu Priya KMN




Suchitra

Suchitra

Thejavathy...



yogita naik

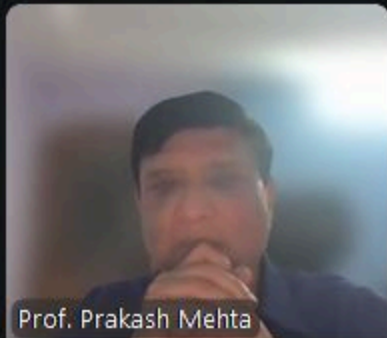
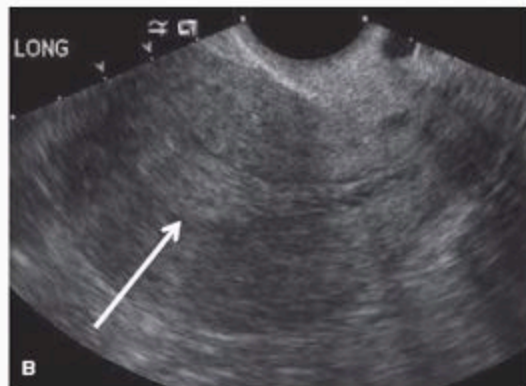


Prof. Prakash ...

55 years old P2L2 post menopausal woman seen with on and off spotting for 4 months; she has no history of any medication and has a family history of endometrial cancer. Her US is as follows

TVS- 7 mm endometrial thickness

1. What is generally the most common cause of PMB?-1 mark
2. What is the incidence of significant pathology in women with PMB?-1 mark
3. What is the preferred gold standard diagnostic investigation?- 1 mark
4. Name an alternative investigation modality and its disadvantage?-1 mark
5. What is the technique of measurement of Em thickness on scan and what is the cut off and its NPV?- 2 marks



Suchitra

S

Suchitra

Srimathy R...

Dr.Vish...



Dr.Vishnu ...

Dr.Nagamani...

Aasya (CLIRNET)

Suchitra



yogita naik




Srimathy Raman

(CLIRNET)

Suchitra

1/2

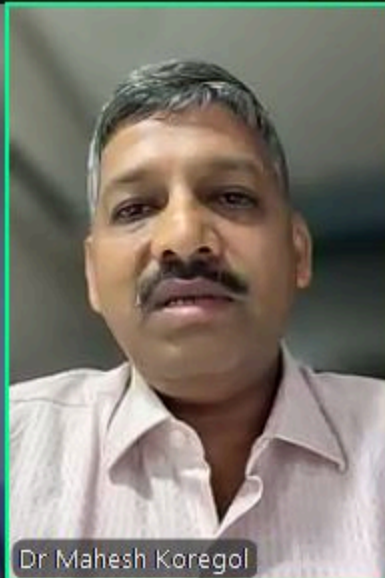1/2



Parineeta Bansal



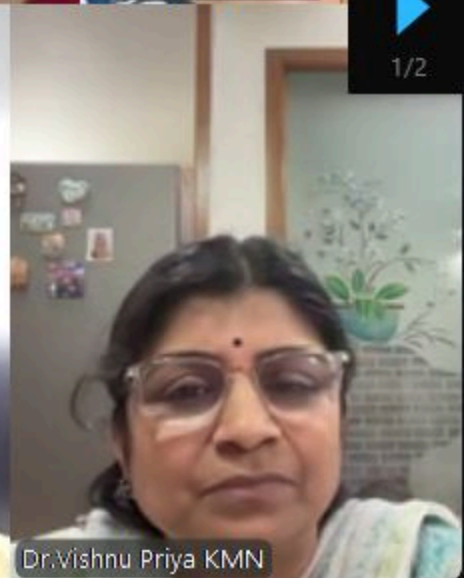
Prof. Prakash Mehta




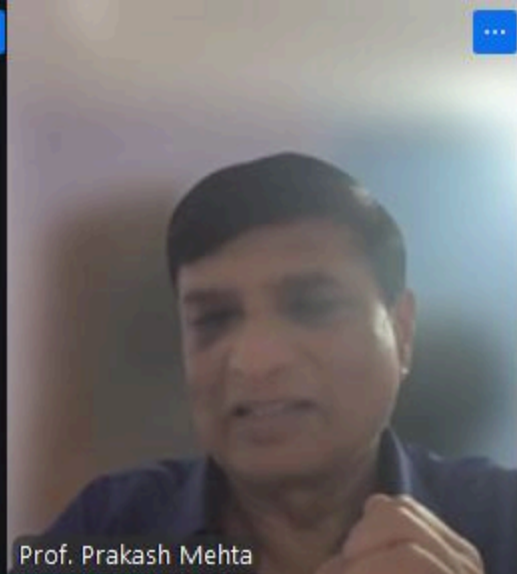
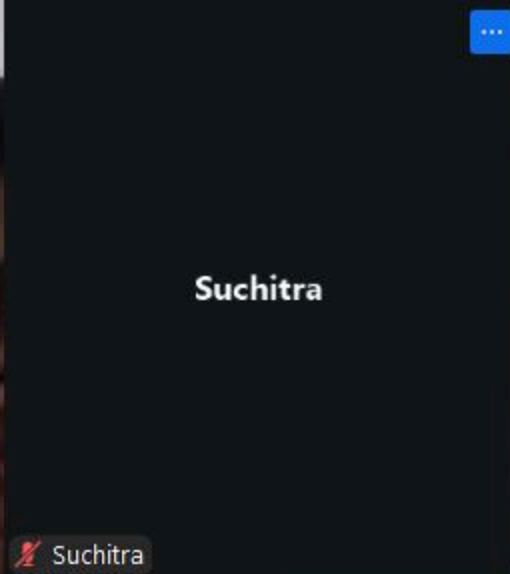
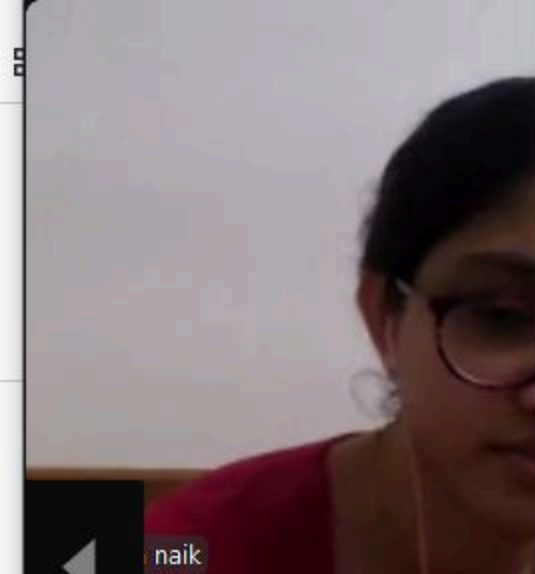
Dr Mahesh Koregol



Dr Rajini Uday



Dr. Vishnu Priya KMN

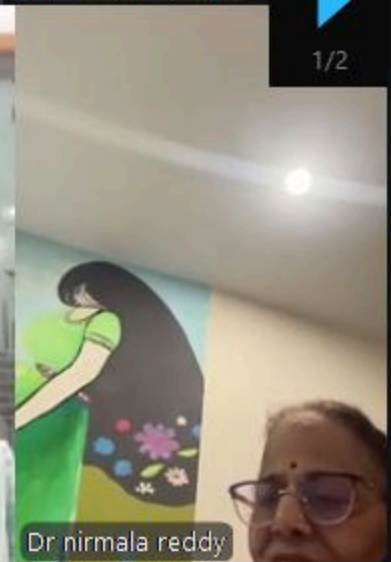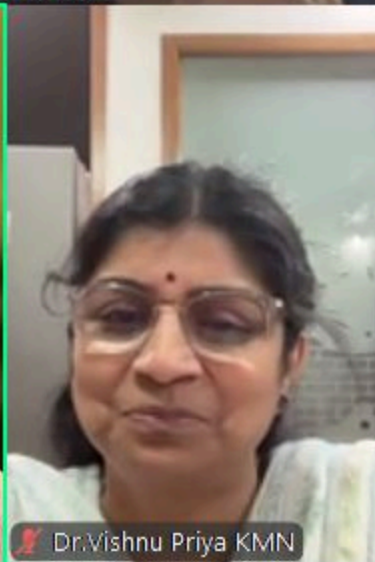



naik

Suchitra

Prof. Prakash Mehta

Srimathy Raman



Dr.Nagamani Tyagaraj

Rajini's iPhone

Dr Mahesh Koregol

Dr.Vishnu Priya KMN

Dr.nirmala reddy